

Original Article

# Immunohistochemical Expression of Vitamin-D Receptor in Oral and Skin Squamous Cell Carcinoma of a Black African Subpopulation

AO Adisa<sup>1,3</sup>, SE Udeabor<sup>3,4</sup>, GO Ogun<sup>2</sup>, A Orłowska<sup>3</sup>, RA Sader<sup>3</sup>, S Ghanaati<sup>3\*</sup>

<sup>1</sup>Oral Pathology Department, College of Medicine, University of Ibadan, Nigeria

<sup>2</sup>Pathology Department, College of Medicine, University of Ibadan, Nigeria

<sup>3</sup>Frankfurt Orofacial Regenerative Medicine (FORM) Lab, Department for Oral, Cranio-Maxillofacial and Facial Plastic Surgery, Medical Center of Goethe University Frankfurt, Frankfurt am Main, Germany

<sup>4</sup>Oral and Maxillofacial Surgery Department, College of Dentistry, King Khalid University, Abha, Saudi Arabia

## ABSTRACT

**Objective:** The nuclear vitamin D receptor (VDR) is involved in multiple pathways that have a role to play in the biology of cancer. Recent evidence indicates that the active form of vitamin D (1 $\alpha$ , 25-dihydroxycholecalciferol) (VD) exhibits several anti-growth effects. Thus it is useful as an anti-neoplastic agent in several human malignancies. We aim to analyze the expression of VDR in skin and oral squamous cell carcinomas (skin SCC and OSCC) from a black African sub-population to determine potential for active VD therapy in such patients.

**Design:** Nineteen formalin fixed paraffin embedded (FFPE) blocks of OSCC and 15 Skin SCC FFPE were prepared for Abcam Rabbit polyclonal Anti-Vitamin D Receptor antibody ChIP Grade (ab3508). Nuclear brown staining was considered as positive for VDR. The Sinicrope scoring method was used to evaluate the stained epithelial cells. All slides were viewed with a Nikon ECLIPSE 80i microscope and microphotographs recorded.

### \*Corresponding Author

Dr. Shahram Ghanaati  
Frankfurt Orofacial Regenerative Medicine (FORM) Lab,  
Department for Oral, Cranio-Maxillofacial and Facial Plastic  
Surgery, Medical Center of Goethe University Frankfurt,  
Frankfurt am Main, Germany.  
Email: Shahram.Ghanaati@kgu.de  
Phone: +49 69 6301 3744  
Fax: +49 69 6301 3785

**Results:** Among 15 moderately differentiated OSCC 7 (46.7%) showed moderate to strong positivity for VDR, while 8 were weak or negative for VDR. Among 10 well-differentiated SCC of the skin, 8 (80%) cases showed moderate to strong VDR positivity, while 2 cases showed weak expression. Overall, approximately the same number of OSCC (9 cases) and Skin SCC (10 cases) expressed moderate to strong positivity for VDR.

**Conclusion:** In our study, we noted that the OSCC and skin SCC have similar number of cases expressing moderate to strong positive staining for VDR. Thus we suggest that the chemotherapeutic role already established for VD is of relevance in OSCC and skin SCC in black Africans.

## INTRODUCTION

The nuclear vitamin D receptor (VDR) is involved in multiple pathways that have many points of convergence. Some of these pathways are implicated in carcinogenesis thus the suggestion that VDR has a role to play in the biology of cancer [1]. Recent evidence indicates that the active form of vitamin D (1 $\alpha$ , 25-dihydroxycholecalciferol) (VD) exhibits several different effects on normal and cancerous cells, including up-regulation of anti-

**Keywords:** Immunohistochemistry, Vitamin-D, Squamous cell carcinoma, African

proliferation and pro-apoptotic factors, as well as inhibition of cell-cycle promoters and growth factor signaling pathways. Thus it is useful as an anti-neoplastic agent in several human malignancies [2]. Breast cancer patients with high immune-reactive scores for VDR were reported to have better progression free survival [3].

Studies in cell and animal model systems, as well as clinical trials have recognized the potential usefulness of VD and VD analogues as agents that enhance the anti-proliferative/cytotoxic effects of chemotherapy and ionizing radiation. Thus, at concentrations that produce limited hypercalcemia, these agents may be used as adjuncts to conventional chemotherapy and radiotherapy [4]. It is therefore useful to establish VDR and VD status in Black Africans with cancer. Especially since it has been reported that non-Caucasians have lower VD concentrations due to higher levels of melanin, which reduces the amount of endogenously produced VD [5].

We aim to analyze the expression of VDR in skin and oral squamous cell carcinomas (skin SCC and OSCC) from a black African sub-population to determine potential for active VD therapy in such patients.

## Methods

**Samples:** Nineteen formalin fixed paraffin embedded (FFPE) blocks of OSCC and 15 Skin SCC FFPE from the Oral Pathology and Pathology Departments of the University College Hospital, University of Ibadan Nigeria were sectioned and stained with hematoxylin and eosin for re-evaluation and inclusion. At the Frankfurt Orofacial Regenerative Medicine (FORM) Lab, Department for Oral, Cranio-Maxillofacial and Facial Plastic Surgery, Medical Center of the Goethe University Frankfurt, Frankfurt am Main, Germany, sections were prepared for immunohistochemistry to VDR.

**Immunohistochemistry:** All the sections were deparaffinized using xylene and hydrated with alcohol. The tissue were immersed in heat-induced epitope retrieval 10mMol citrate buffer pH 6.0 (TA-250-PM1X), diluted 1:100 with distilled water and incubated at 95<sup>o</sup> C for 20 minutes. They were cooled in the buffer for 20 minutes and then rinsed in PBS for 5 minutes. Positive and negative controls were employed. Thermo-Scientific peroxidase blocking reagent was added to each section for 15 minutes, and the sections were rinsed in 0.1% TBST for 5 minutes. The specimen were incubated for 60 minutes with 1:2000 dilutions of Abcam Rabbit polyclonal Anti-Vitamin D Receptor antibody ChIP Grade (ab3508) and then rinsed with TBST, followed by incubation with pre-diluted (ready-to-use) UltraVision Quanto Detection System/Horse Radish Peroxidase for 15 minutes. One ml of diaminobenzidine substrate with one drop of diaminobenzidine chromogen was added to cover the slides, followed by incubation in a humidity chamber for 5 minutes. The sections were then immersed in aqueous Gill's hematoxylin for 10 seconds and rinsed in distilled water for 5 minutes. The tissue was dehydrated and subsequently rinsed with xylene. DPX was applied, and a cover slip placed. Nuclear brown staining was considered as positive for VDR.

**Scoring method:** The Sinicrope scoring method was used to evaluate both the intensity of the immunohistochemical staining and the proportion of the stained epithelial cells. The staining intensity was classified as weak, moderate, or strong. The positive cells were quantified as a percentage of the total number of epithelial cells and assigned to one of five categories (0, <5%; 1, 5–25%; 2, 26–50%; 3, 51–75%; 4, > 75%). The percentage of positivity of the tumor cells and the staining intensities were then multiplied in order to generate an immuno-reactive score. The product of the proportion and intensity scores were calculated such that a final score of 0

indicated no expression, 0–4 indicated weak expression, 5–8 indicated moderate expression and 9–12 indicated strong expression.

All slides were viewed with a Nikon ECLIPSE 80i microscope (Nikon, Tokyo, Japan) and microphotographs of the stained sections were recorded with a connected digital camera DS-Fi1 together with a Nikon digital sight control unit (Nikon, Tokyo, Japan).

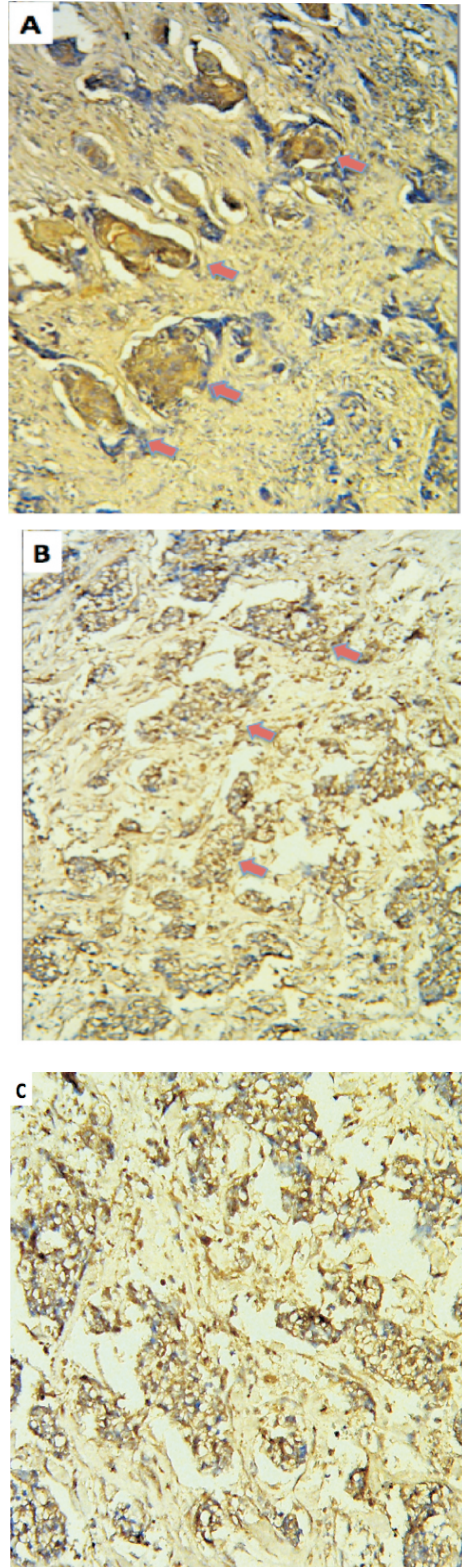
**RESULTS**

Among 15 moderately differentiated OSCC 7 (46.7%) showed moderate to strong positivity for VDR, while 8 were weak or negative for VDR. Among 10 well-differentiated SCC of the skin, 8 (80%) cases showed moderate to strong VDR positivity, while 2 cases showed weak expression. Overall, approximately the same number of OSCC (9 cases) and Skin SCC (10 cases) expressed moderate to strong positivity for VDR (Table1).

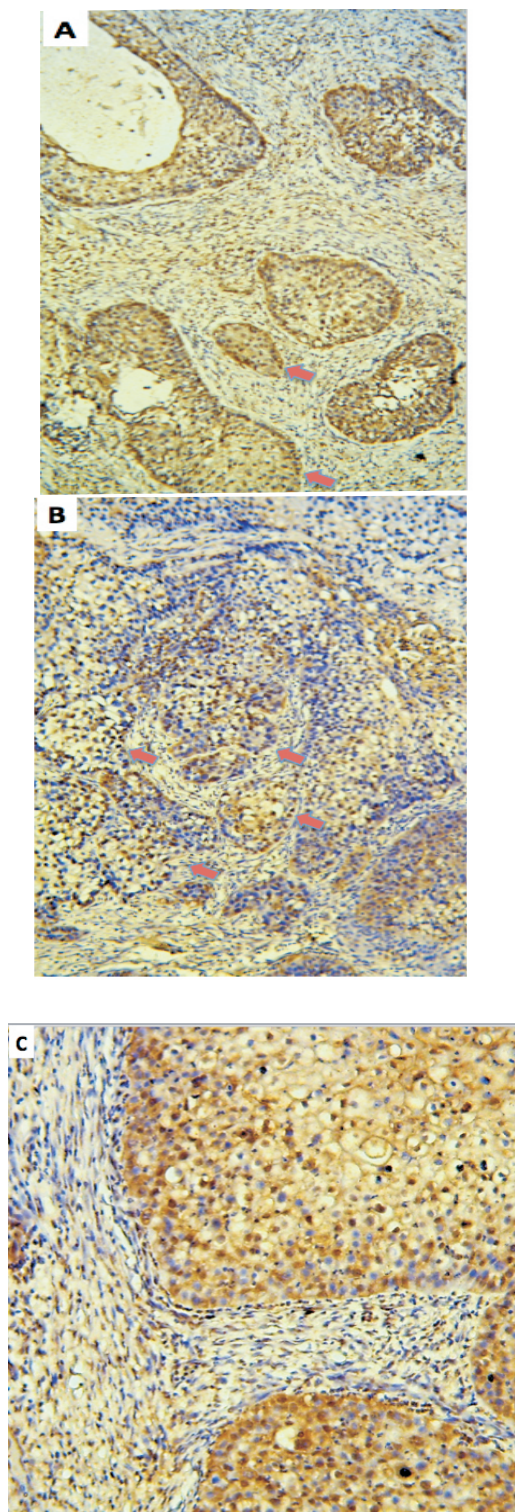
**Table 1: Anti-VDR immunostaining in different grades of OSCC and Skin SCC**

Grade of cancer	Immuno-reactive score	OSCC	Skin SCC
WDSCC	Negative	0	0
	+	1 (5.3%)	2 (13.3%)
	++	1 (5.3%)	1 (6.7)
	+++	1 (5.3%)	7 (46.7%)
MDSCC	Negative	2 (10.5%)	1 (6.7)
	+	6 (31.6%)	2 (13.3%)
	++	1 (5.3%)	2 (13.3%)
	+++	6 (31.6%)	0
PDSCC	Negative	1 (5.3%)	0
Total		19 (100%)	15 (100%)

WDSCC- well differentiated squamous cell carcinoma, MDSCC- moderately differentiated squamous cell carcinoma, PDSCC- poorly differentiated squamous cell carcinoma, + weak, ++ moderate, +++ strong.



**Figure1:** Sections A (++) and B (+++) of OSCC showing nuclear positivity (red arrows) for malignant nests of epithelial cells X40. C is an enlarged version of B



**Figure 2:** Sections A (+++) and B (++) of skin SCC showing nuclear positivity (red arrows) for malignant nests of epithelial cells X100. C is an enlarged version of B

## DISCUSSION

We wanted to test the VDR expression in OSCC and skin SCC of black-skinned persons residing in Africa, and to compare this expression based on a sun-exposed site and a non sun-exposed site. In our study, we noted that disregarding grade of cancer; the OSCC and skin SCC have similar number of cases expressing moderate to strong positive staining for VDR. Thus we suggest that the chemotherapeutic role already established for VD [6] is of relevance in OSCC and skin SCC in black Africans. By contrast, the cases of skin SCC that expressed weak or negative VDR staining are poor prognostic cases. This is because VDR and its ligand have been described as a tumor suppressor unit in skin via regulation of the sonic hedgehog and beta-catenin signaling pathways [6] and the absence of this only further complicates our cases. When we consider the grade of the cancer, only 46.7% of moderately differentiated OSCC was strongly positive while 80% of well-differentiated skin SCC was strongly positive for VDR. In a previous study, Grimm et al [7] demonstrated low VDR expression as an adverse prognostic factor for the survival of patients with OSCC. This may imply a potentially higher response rate of well-differentiated skin SCC to VD therapy than any grade of OSCC.

## CONCLUSION

A higher percentage of skin SCC expressed strong VDR compared to the OSCC cases, and thus we suggest that this may be a potential target for personalized treatment of skin cancer and may also be a marker of good prognosis, but further studies are required.

## ACKNOWLEDGMENT

The authors wish to thank Mrs. Verena Hoffmann and Mr. Babajide Okedere for all the technical assistance provided during the course of this study.

## REFERENCES

1. Slattery ML. Vitamin D Receptor Gene (VDR) Associations with Cancer. *Nutr Rev.* 2007; 65: S102–S104.
2. Russell DS, Rassnick KM, Erb HN, Vaughan MM, McDonough SP. An immunohistochemical study of vitamin D receptor expression in canine cutaneous mast cell tumours. *J Comp Pathol.* 2010;143(2-3):223-6.
3. Nina D, Bettina T, Doris M, Miriam L, Julia G, , Christian D, Klaus F, Udo J. The Association between Vitamin D Receptor Expression and Prolonged Overall Survival in Breast Cancer *J Histochem Cytochem.* 2012; 60(2): 121–129.
4. Gewirtz DA, Gupta MS, Sundaram S. Vitamin D3 and vitamin D3 analogues as an adjunct to cancer chemotherapy and radiotherapy. *Curr Med Chem Anticancer Agents.* 2002;2(6):683-90.
5. Clemens TL, Adams JS, Henderson SL, Holick MF. Increased skin pigment reduces the capacity of skin to synthesise vitamin D3. *Lancet.* 1982 9;1(8263):74-6.
6. Daniel DB, Yuko O, Arnaud T. The vitamin D receptor: A tumor suppressor in skin. *Discov Med.* 2011; 11(56): 7–17.
7. Grimm M, Alexander D, Munz A, Hoffmann J, Reinert S. Is 1,25-dihydroxyvitamin D3 receptor expression a potential Achilles' heel of CD44+ oral squamous cell carcinoma cells? *Target Oncol.* 2013;8:189-201.