

Case Report

Intermittent Testicular Torsion in an African Adult Patient: Sonographic Doppler findings of an uncommon and challenging diagnosis

Bornface Chinene ¹, Lavin Mutandiro ¹, Damian Murambasvina ²

¹*School of Radiography, Harare Institute of Technology, Zimbabwe*

²*Carestream Ultrasound Center, Harare, Zimbabwe*

ABSTRACT

Testicular torsion is a well-known urological emergency most common in the paediatric population. However, testicular torsion is not an all-or-none phenomenon and can be of complete, partial or intermittent types. Intermittent testicular torsion is rare and can be misdiagnosed even in a paediatric population. Testicular torsion in adults is less common, and intermittent testicular torsion in adults is even less reported and may not be considered in the differential diagnosis of acute testicular pain, leading to misdiagnosis. There is paucity of literature commenting on sonographic findings of testicular torsion in African adults. We report a rare case of a 35-year-old African man who previously was clinically diagnosed with epididymo-orchitis. On a successive episode, he underwent sonographic Doppler evaluation, and was found to have intermittent testicular torsion.

INTRODUCTION.

Testicular torsion (TT) is a well-known urological emergency most common in the paediatric population¹. However, it is not an all-or-none phenomenon and can be of complete, partial or intermittent types². Intermittent testicular torsion

(ITT) is an episode of acute torsion of the spermatic cord that resolves spontaneously³. It can occur at any age but typically occurs in young males below 25; this is an extremely painful condition and is the most common cause of testicle loss and infertility⁴. Intermittent testicular torsion may be misdiagnosed even in a pediatric population. Testicular torsion in adults is less common, and ITT in adults is even less reported and may not be considered in the differential diagnosis of acute testicular pain¹. There is paucity of literature commenting on sonographic findings of testicular torsion in African adults. We report a case of a 35-year-old African man who previously was clinically diagnosed with epididymo-orchitis (EO). On a successive episode, he underwent sonographic Doppler evaluation, and was found to have ITT.

CLINICAL HISTORY

A 35 year old man with 4hour severe acute right groin pain was referred to an A&E department at a private hospital. A general examination of the testis, blood and urine were all normal. There was no discharge from the urethra and no presenting urinary symptoms. On further questioning, the patient stated that he had a similar episode twice prior to the current one. The first episode, was when he was in high school at the age of 16 after riding a bicycle. The episode was accompanied by vomiting but the

Corresponding Author:

Bornface Chinene
16422 Sunningdale 2
Harare, Zimbabwe

Email: bchinene@hit.ac.zw, bornfacechinene@gmail.com

Telephone: +263773270576

Keywords: *Testicular torsion, intermittent testicular torsion, epididymo-orchitis, Doppler, ultrasound*

pain had spontaneously resolved after a few hours. The second episode happened about a year ago. The patient was rushed to a nearby council clinic where he was given pain killers and antibiotics and discharged. Clinically epididymo-orchitis was diagnosed. No ultrasound scan was requested on both previous episodes. Because of the previous episodes he decided to seek specialist care and hence an ultrasound scan was requested by the Urologist.

TECHNIQUE

Scrotal sonographic imaging was performed to diagnose or exclude testicular torsion, epididymo-orchitis and acute idiopathic scrotal oedema. The scan was performed using a Mindray machine with a 12-5 MHz linear probe. Color Doppler imaging and spectral Doppler velocity measurements were done in addition to gray-scale imaging.

ULTRASOUND FINDINGS.

- i. The left testicle had a normal echotexture and smooth outline with no solid or cystic lesions seen.
- ii. The left testicle had normal vascularity with normal arterial waveform shape. The right testicle arterial waveform demonstrated a low resistance arterial flow with peak systolic velocity of 7.42cm/s (Figure 1).
- iii. The arterial waveform of the right testicle showed absence of diastolic flow (Figure 2).
- iv. No abnormal masses or fluid collections were seen in both right and left scrotal compartments. Both epididymides appeared normal. Both scrotal walls appeared normal with no varicoceles detected.

The conclusion was findings were consistent with ITT. In view of the above findings the patient was immediately admitted and sent for surgery. The urologist confirmed the diagnosis of ITT.

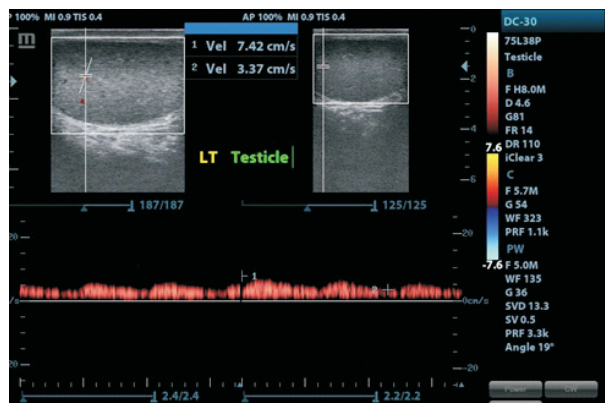


Figure 1

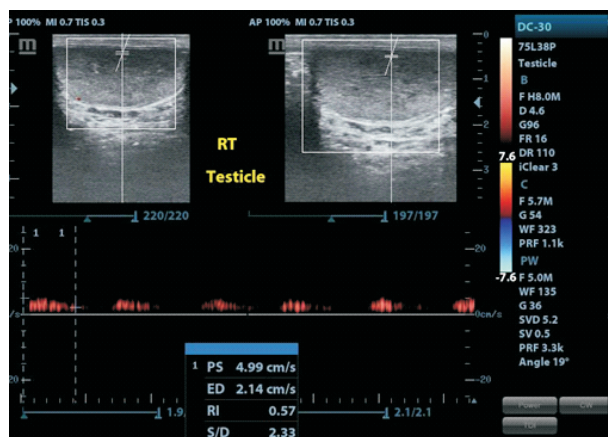


Figure 2

DISCUSSION

The differentiation between ITT and EO is a clinical challenge in up to 50% of the cases, since scrotal pain, swelling, and redness or tenderness are clinical symptoms common to these two entities⁵⁻⁶. Though the diagnosis of ITT is usually made clinically, ultrasound is helpful in confirming the diagnosis. Ultrasound is the modality of choice because it is simultaneously able to assess the structure of the testis as well as the vascularity, all without subjecting the gametes to ionizing radiation⁷. However, there is also an overlap in the gray-scale and Doppler findings of EO and ITT with torsion-detorsion syndrome presenting diagnostic dilemmas for

sonographers, radiologists and urologists⁸. Nevertheless, accurate diagnosis is imperative because ITT is treated surgically, whereas epididymitis-orchitis is treated medically. Failure to recognize the existence of ITT can lead to repeated attacks of scrotal pain, swelling, and possibly the loss of a testicle. In this case, failure to recognize ITT in the first episode lead to repeated scrotal pain attacks.

In this case, the second episode of the acute scrotal pain was misdiagnosed as EO because the patient was older. This is consistent with the literature as reported cases of ITT have been misdiagnosed because there are a few case reports on this condition in adults. Davol and Simmons⁹, reported a case of a 68-year-old man initially diagnosed with epididymo-orchitis, who, on surgical exploration, was found to have intravaginal testicular torsion. In a study by Eaton *et al.*⁴, 63.9% of the patients had been wrongly diagnosed with varicoceles before a diagnosis of ITT was made. This therefore underscores the need to treat all acute scrotal pain symptoms in adults as torsion and hence refer them for ultrasound evaluation.

High-frequency transducer sonography including pulsed and color Doppler vascular imaging is the primary imaging modality of choice for assistance in evaluation of the acute scrotum¹⁰, but it was not used in this patient in the first two episodes. Shortage of ultrasound equipment in Zimbabwean primary health care settings¹¹, may have been a contributing factor for this diagnosis to be missed the previous two occasions. According to Dubinsky, Chen and Maklad¹², diagnosis of TT based on clinical findings without the use of imaging has a false-positive rate of 50%. Recent researchers have emphasized the use of Color Doppler imaging and spectral Doppler velocity measurements in addition to gray scale in the assessment of ITT. This is because these cases

have either subtle decreased flow or flow that appears to be symmetrical with the contralateral testis, and symptoms can wax and wane¹.

In this case, even though blood flow was noted on Colour Doppler, further interrogation on Spectral Doppler revealed absence end-diastolic flow which confirmed a diagnosis of ITT. This was in harmony with findings by Cassar *et al.*¹³, most of the cases of ITT were diagnosed only after careful examination of the spectral Doppler waveform characteristics. The findings, therefore, highlight the importance of not relying on just grayscale and Color Doppler but also Spectral Doppler measurements in the assessment of suspected ITT. Previous studies have reported the sensitivity of color flow Doppler in pediatric patients is 90% to 100%, and specificity is nearly 100%. In the adult population, a similar sensitivity of 80% to 98% and specificity of 97% to 100% have been reported. The sensitivity of spectral Doppler ranges from 67% to 100%⁶.

Another imaging modality that has been used to evaluate patients with testicular torsion is subtraction dynamic-contrast enhanced MRI. This imaging modality can determine decreased testicular perfusion and hemorrhagic necrosis¹⁴, however, scrotal MRI is not time- or cost-effective in the diagnosis of the acute scrotum.

CONCLUSIONS

This case presented a diagnosis of ITT in an adult patient showing that this condition may happen at any age. Therefore, the use ultrasonography should be strongly considered if the history and physical examination is suggestive of testicular torsion, regardless of patient age. Additionally, this case also highlights the importance of making use of spectral Doppler to assess the waveform for any changes in shape or blood velocity.

DECLARATION OF INTERESTS

No conflict of interest declared

FUNDING

The authors received no financial aid for the research, authorship, and/or publication of this article

REFERENCES.

1. Al-Kandari AM, Kehinde EO, Khudair A, Ibrahim H, ElSheemy MS, Shokeir AA. Intermittent Testicular Torsion in Adults: An Overlooked Clinical Condition. *Medical Principles and Practice*. 2017; 26:30–34. DOI: 10.1159/000450887
2. Bandarkar AN and Blask AR. Testicular torsion with preserved flow: key sonographic features and value-added approach to diagnosis. *Pediatric Radiology*. 2018; 48:735–744. <https://doi.org/10.1007/s00247-018-4093-0>
3. Hayn MH, Herz DB, Bellinger MF and Schneck FX. Intermittent Torsion of the Spermatic Cord Portends an Increased Risk of Acute Testicular Infarction. *Journal of Urology*. 2008; 180(4):1729-32 <https://doi.org/10.1016/j.juro.2008.03.101>
4. Eaton SH, Cendron MA, Estrada CR, Bauer SB, Borer JG, Cilento BG, *et al*. Intermittent testicular torsion: Diagnostic features and management outcomes. *Journal of Urology*. 2005; 174:1532-5.
5. Munden M, Williams J, Zhang W, Crowe JE, Munden RF, Cisek LJ. Intermittent testicular torsion in the pediatric patient: sonographic indicators of a difficult diagnosis. *American Journal of Roentgenology* 201;912–918
6. Patel NU, Drose JA and Russ P. Partial Testicular Torsion and Torsion-Detorsion Syndrome. *Journal of Diagnostic Medical Sonography*. 2013; 29(5) 225–231.
7. Worsley C and Gaillard F. Testicular Torsion. *Radiopaedia*. <https://radiopaedia.org/articles/testicular-torsion>
8. Luker GD, Siegel MJ. Scrotal US in pediatric patients: comparison of power and standard color Doppler US. *Radiology*. 1996. 198:381–385.
9. Davol P. and Simmons J. Testicular torsion in a 68-year-old man. *Urology*. 2005; 66(1):195. doi: 10.1016/j.urology.2005.02.001
10. Dogra V, Bhatt S. Acute painful scrotum. *Radiol Clin North Am*. 2004; 42:349–363.
11. Maborete T, Banhwa J and Pitcher RD. An audit of licensed Zimbabwean radiology equipment resources as a measure of healthcare access and equity. *Pan African Medical Journal*. 2019; 34:60. [doi: 10.11604/pamj.2019.34.60.18935].
12. Dubinsky TJ, Chen P, Maklad N. Color-flow and power Doppler imaging of the testes. *World J Urol*. 1998. 16:35–40.
13. Cassar S, Bhatt S, Paltiel HJ, Dogra VS: Role of spectral Doppler sonography in the evaluation of partial testicular torsion. *J Ultrasound Med*. 2008; 27(11):1629–1638.
14. Watanabe Y, Nagayama M, Okumura A, Amoh Y, Suga T, Terai A, *et al*. MR imaging of testicular torsion: features of testicular hemorrhagic necrosis and clinical outcomes. *J Magn Reson Imaging*. 2007. 26:100–108.