

Case Report

Proxies for Covid-19 Diagnosis for Adults in Resource Limited Settings: A Case Series Study in Zambia

Katongo H. Mutengo¹, John S. Kachimba², Francis Mupeta³

¹Department of Internal Medicine, Livingstone Teaching Hospital, Ministry of Health, Livingstone, Zambia.
Email: katmutengo@yahoo.com.

²Department of Surgery, Livingstone Teaching Hospital, Ministry of Health, Livingstone, Zambia.
Email: jskachimba@yahoo.com.

³Infectious Diseases Unit, Department of Internal Medicine, University Teaching Hospital, Lusaka, Zambia.
Email: mupetaf@yahoo.co.uk.

ABSTRACT

The novel coronavirus disease of 2019 (COVID-19); caused by the severe acute respiratory syndrome coronavirus 2 (SARS-CoV-2), has presented a unique range of clinical manifestations. Thought to be primarily a respiratory disorder during its early outbreak in China in early December of 2019, it has now emerged from various scientific studies that the clinical manifestation of COVID-19 is indeed protean. This paper is aimed at exploring various proxies that can be used to increase the index of suspicion for COVID-19 in resource-limited settings like Zambia by reviewing four cases that presented to our health facilities. We hope this will help reduce healthcare costs through instituting early and more targeted treatment approaches.

INTRODUCTION

Severe acute respiratory syndrome coronavirus 2 (SARS-CoV-2), was the name coined for the virus that appeared to be causing respiratory symptoms among the Wuhan population of China in late 2019. The World Health Organisation (WHO) later named the disease caused by SARS-CoV-2 as coronavirus disease 2019 (COVID-19) and declared it a

Corresponding author:

Katongo H. Mutengo,

Internal Medicine Physician, Department of Internal Medicine, Livingstone Teaching Hospital, Livingstone, Zambia. Email: katmutengo@yahoo.com.

pandemic in February of 2020 .

Over time, researchers from across the world have been challenged to comprehend the dynamics of the disease in the hope of discovering approaches to bring the pandemic to a halt. As the disease is progressing, newer evidence is emerging that COVID-19 not only present with typical symptoms of respiratory infection like cough, fever, sore throat or shortness of breath; but has other manifestations such as hypoxia in the absence of severe respiratory distress, and prothrombic state facilitated by endothelial cell dysfunction (ECD) –. This partially explains some clinical presentations like thrombosis initially thought to be an enigma, and a possible predilection of COVID-19 in diseases with ECD such as advanced age, cardiac diseases, hypertension, diabetes and obesity .

Assessment of ECD requires sophisticated laboratory tests which are beyond the capacity of most resource-limited settings like Zambia. Additionally, the constraints in laboratory confirmation of SARS-CoV-2 in our setting means decision making is often delayed. We aim to use available scientific and anecdotal evidence to propose proxies that resource-limited countries can utilise to rapidly identify high-risk SARS-CoV-2 infected persons to institute early and targeted treatment strategies. We will discuss some of the

Keywords: COVID-19, SARS-CoV-2, proxies.

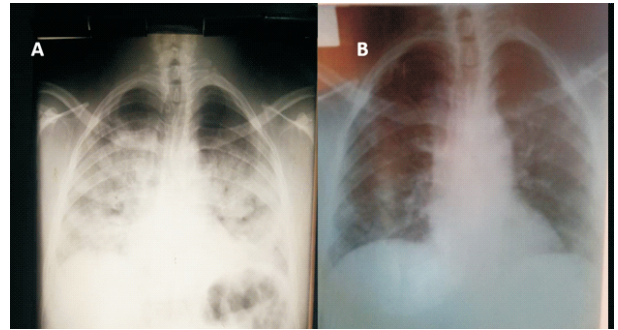
manifestations of COVID-19 in Zambia from the 4 cases illustrated below, to heighten the suspicion for making the diagnosis of the condition. We hope that these recommendations will generate important research, addressing the specificities and sensitivities of the clinical proxies in making a diagnosis of SARS-CoV-2.

Case Summaries

Patient 1 was a 62-year-old male who presented to Livingstone Teaching Hospital (LTH), a tertiary institution in Southern province of Zambia with hyperglycaemia and a febrile illness. He was a known type 2 diabetes and hypertensive patient for over 10 years, and reportedly well controlled on medication. His condition deteriorated within 5 days of admission and was noted to be desaturating and experiencing breathlessness on the 5th day. His peripheral oxygen saturation (SPO₂) was 47% on ambient air. Nasopharyngeal (NP) swab for SARS-CoV-2 reverse transcriptase-polymerase chain reaction (RT-PCR) was initially obtained upon admission. He was presumed to have COVID-19 based on low saturations and acute respiratory symptoms. Presumptive COVID-19 local treatment protocol was instituted with oxygen therapy 6L via nasal prongs, dexamethasone 6mg twice daily for 10 days, low-molecular-weight-heparin (LMWH) 80mg once daily for at least five days and azithromycin 500mg stat then once daily for 3 days. He deteriorated in less than 24 hours and died. Escalation of oxygen was not done due non-availability of the service at the time of admission. His RT-PCR result was positive for SARS-CoV-2 two weeks after demise.

Patient 2 was a 46-year-old male with a history of hypertension who presented to LTH with breathlessness and a mild cough. He had no fever and the SPO₂ was ranging between 75- 82% on ambient air without any evidence of cyanosis. Chest x-ray showed widespread infiltrations consistent with a ground-glass appearance [figure 1A]. The local treatment protocol was initiated for SARS-CoV-2 using principles of oxygenation (6l via nasal

prongs), awake pronation, systemic corticosteroids and anticoagulation. Additionally, low-risk adjunct treatments such as vitamin C and N-acetyl-cysteine were given. His test result confirmed SARS-CoV-2 with RT-PCR one week after admission. He made a good recovery and was discharged on day 11 with improvement in his chest x-ray findings [figure 1B]



Ground glass appearance on chest x-ray of patient 2 on admission [Figure 1A] and 10 days after treatment [Figure 1B].

Patient 3 was a 36-year-old male who presented to LTH with non-specific symptoms of fatigue, general body malaise and headache but denied cough or fever. Past medical history was non-revealing. Clinically, he was not cyanosed and was not in obvious respiratory distress. Routine SPO₂ showed he was saturating between 82-84% on ambient air. He was treated as possible COVID-19 pneumonia and initiated on treatment similar to patient 1. He progressed well and was discharged on day 6 into home isolation. The RT-PCR result later confirmed the diagnosis 10 days after discharge.

Patient 4 was a 57-year-old man from a high-density area with no previous comorbidities presented to the emergency room of University Teaching Hospital, Lusaka Adult Hospital, with a 1-day history of malaise, dry cough, headache, poor appetite and swelling of both legs. The further evaluation confirmed the deep vein thrombosis (DVT) of the left leg and radiology features consistent with COVID-19 pneumonia. He was treated presumptively as COVID-19 pneumonia and a prothrombotic state. He received oxygen therapy via nasal prongs, Azithromycin 500mg once daily, ceftriaxone 1g twice daily for 5 and 7 days

respectively, LMWH 60mg twice daily subcutaneously and warfarin 5mg once daily. A nasopharyngeal swab was positive for SARS-CoV-2 infection 3 days after admission. Baseline D-dimer was 7500ng/ml and INR 0.78 which increased to 1.76 one week after anticoagulation. He was discharged 10 days later with an improvement of pneumonia but persistent DVT in both legs 3 weeks later.

Discussion

Most clinicians in our setting rely on laboratory confirmation of SARS-CoV-2 before any clinical decisions can be made. That would have been the case in the given case series especially that confirmatory diagnosis of COVID-19 is only made with RT-PCR. As indicated by the clinical scenarios above, most of our patients had severe hypoxia which was not consistent with the clinical presentation. What has been observed so far is that the physiological and pathological changes characterising COVID-19 involve an inflammatory response and a prothrombotic state. We, therefore, suggest the following proxies for COVID-19 diagnosis using available scientific evidence.

1. Chest x-ray and pulse oximetry

Some COVID-19 patients appear to have a disconnect between the extent of hypoxaemia and signs of respiratory distress which is termed “happy hypoxia” as was the case with patient 3. Dhont *et al* reported that before the onset of dyspnoea; defined as laboured breathing as opposed to tachypnoea which is fast breathing, various mechanisms are involved which causes an imbalance between pulmonary ventilation and capillary blood flow. Proposed mechanisms include; intrapulmonary shunting, loss of perfusion regulation, impaired diffusion, and most importantly the emerging hallmark of COVID-19, intravascular microthrombi

It has been noted that lung compliance is preserved in hypoxic COVID-19 on ventilation atypical of acute severe respiratory distress syndrome (ARDS). Microthrombi occurring in the pulmonary

vasculature in COVID-19 has been postulated to be responsible for hypoxia as it alters lung perfusion, impairs gas exchange and results in loss of oxygen transfer capacity of haemoglobin. It is further proposed that if these processes are not identified and managed early through anti-inflammatory medication, lung recruitment strategies such as awake prone ventilation and anticoagulation, they may lead to rapid clinical deterioration requiring more expensive interventions such as invasive ventilation and often lead to poor clinical outcomes as was noted in our first patient.

However, to identify these processes accurately, extensive tests are required. These tests, among many, include; assessing the pressure of arterial oxygen (P_aO_2) and carbon dioxide (P_aCO_2) dissolved in the blood, blood pH, lung diffusion capacity (DLCO), angiotensin II levels, coagulation profiles, high-resolution CT-imaging, Ventilation/Perfusion (V/Q) scans and multiple inert gas elimination technique (MIGET). However, these tests are scarce in Zambia and likely mirrored in other resource-limited settings. We propose that using pulse oximetry which measures the SpO_2 might be a significant intermediary in identifying COVID-19 presenting as “happy hypoxic”. Happy hypoxia and ARDS can accurately be identified by pulse oximetry and the Kigali criteria respectively. This was evidenced in our cases where management was instituted immediately without hanging tight for the long procedures of test results.

2. Thrombotic events and Procoagulation profiles

Studies have shown an increase in thrombotic events such as strokes, pulmonary embolism and myocardial infarction in COVID-19 patients. Additionally, a study by Ackermann *et al* showed that the lungs of patients who died from SARS-CoV-2 infection had 9 times more thrombi formation when compared to the lungs of patients with influenza.

SARS-Cov-2 infects the human cells using the angiotensin-converting enzyme 2 (ACE 2) receptors

. The receptors are expressed in the lungs, heart, kidneys, intestines and endothelial cells. SARS-CoV-2 primary entry point is through the respiratory tract but may cause widespread infection in severe disease. The ACE 2 receptor acts as a catalytic site for the ACE 2, an enzyme that degrades angiotensin 2 (ATII) to angiotensin-1,7 (AT-1,7) . ATII cause vasoconstriction, increase cardiac contractility and stimulate the production of aldosterone among other neurohormonal functions. However, there is scientific evidence that ATII also promotes inflammatory response by stimulating NADPH-oxidase; an enzyme responsible for the generation of the reactive oxygen species (ROS) such as super oxides . Super oxides can induce endothelial cell damage and activate polymorphonuclear cells (PMNs) recruiting them to the site of injury . Chemical mediators produced by the polymorphonuclear leukocytes further cause cellular damage creating a vicious inflammatory cycle .

On the other hand, AT-1,7 causes vasodilatation, inhibits oxidative cellular damage by blocking NADPH-oxidase and stimulate the production of nitric oxide (NO) via nitric synthase pathways . All these cellular processes have a protective effect on the endothelium by counteracting effects of ATII. It has been theorised that in COVID-19, the SARS-CoV-2 binds to the ACE 2 receptor inhibiting its catalytic effect . This downgrades the function of AT-1,7 while there are unrestrained effects of ATII induced endothelial injury . Platelets tend to adhere faster to injured endothelium due to the excess release of von Willebrand factor (vWF); a glycoprotein which facilitates platelet adhesion and aggregation as a response to ECD occurring due to injury . ECD from different conditions, including COVID-19, causes high levels of circulating multimeric endothelial-associated vWF and factor VIII . The multimeric form of vWF performs its hemostatic functions *in vivo* by binding to factor VIII, to platelets surface glycoproteins and certain elements of connective tissue resulting in widespread thrombus formation. This may explain

why thrombotic events are seen in COVID-19 patients including our patient 4. We, therefore, propose that thrombotic events such as stroke, pulmonary embolism, myocardial infarction, deep venous or arterial thrombosis should have samples collected for SARS-CoV-2 testing, while anticoagulation therapy or thrombolytic therapy, if possible, must be instituted immediately.

Also, most severe cases of COVID-19 patients with thromboembolic pulmonary complications have been shown to present with a pro-coagulant profile, elevated D-dimers and angiogenesis . Increased circulating D-dimer concentrations and high cardiac enzymes even with normal fibrinogen levels and platelets are key early features of severe pulmonary intravascular coagulopathy related to COVID-19 . This has been attributed to thrombosis with fibrinolysis and stress on the myocardium.

A study by Ranucci *et al* in critically ill COVID-19 with ARDS indicated procoagulant state with high clot strength predominantly from fibrinogen and platelet contribution . The study also noted a positive correlation between interleukin-6 levels and fibrinogen levels although this was ameliorated with anticoagulation therapy. IL-6 has been noted to induce synthesis of tissue factor, fibrinogen, and increased platelet production . Tissue factor also triggers thrombin formation. The interplay of these factors is generally responsible for a procoagulant state.

The procoagulant state indicated by elevated D-dimers ($\geq 2.0 \mu\text{g/mL}$) as was the case with patient 4, factor VIII and vWF have also been associated with poor outcomes in COVID-19 patients . We suggest that enhancing D-dimer testing in a hospital setting can be used to assess individuals at high risk of having COVID-19, and assist in the therapeutic interventions and prognosis of COVID-19.

3. Hyperglycaemia

From our case scenarios, the worst outcome was noted with patient 1 who had diabetes and hypertension. There is little epidemiological

evidence to show that people with diabetes have a higher risk of getting COVID-19, although diabetic patients with hyperglycaemia have been shown to have worse outcomes. However, there has been a notable trend of new-onset diabetes, as well as complications such as diabetic ketoacidosis (DKA) in pre-existing diabetes in COVID-19 hence the credence that the relationship between COVID-19 and diabetes may be bidirectional –.

An impaired immune response like the pre-existing proinflammatory state is postulated to reduce viral clearance and worsen macrophage activation syndrome (MAS), also known as a cytokine storm. Scientific evidence indicates a strong association between diabetes mellitus and abnormal secretion of proinflammatory mediators such as interleukin 6, tumour necrosis alpha (TNF- α) and interferons. The procoagulant state has also been noted to be significantly higher in COVID-19 pneumonia with diabetes compared to those without diabetes. Diabetes also tends to commonly occur with other conditions known to cause oxidative stress such as hypertension and obesity. The factors outlined above can increase the virulence of SARS-CoV-2 and thus may be responsible for worse outcomes and are also implicated in the development of hyperglycaemia, either worsening or new-onset.

Furthermore, studies have shown that some viruses, including the 2003 SARS-CoV are diabetogenic. More scientific evidence is needed as to whether this holds for SARS-CoV-2 and may explain new-onset hyperglycaemia seen in some COVID-19 pneumonia, especially that ACE-2 receptors are also widely expressed in endocrine tissues including pancreatic beta cells. Although we could not do blood glucose in other patients, the case of patient 1 as highlighted the need. We propose routine glucose check for hospital admissions and urgent test for

SARS-CoV-2 in those with new-onset or worsening hyperglycaemia.

CONCLUSION AND RECOMMENDATIONS

Because of the prevailing situation of the high cost of running RT-PCR testing for the laboratory confirmation of SARS-CoV-2 most resource-limited settings like Zambia, it is prudent that high-risk category of patients is recognized early, even those falling outside the known typical symptoms of COVID-19 patients such as fever and respiratory symptoms. We have therefore proposed the flow and management of COVID-19 as outlined in figure 2 following case definitions defined by WHO in table 1.

Figure 2: Algorithm for facility management of COVID-19 cases.

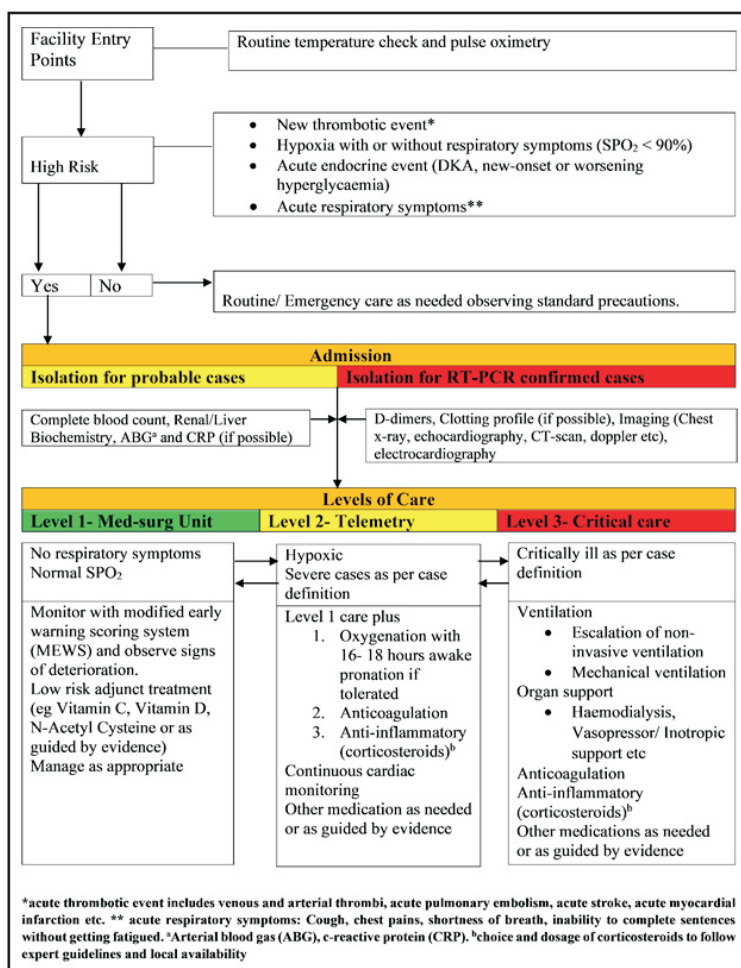


TABLE 1: Mutually exclusive case definitions according to the September 2020 World Health Organisation living guidelines.

Critical COVID-19	Defined by the criteria for acute respiratory distress syndrome (ARDS), sepsis, septic shock or other conditions that would normally require the provision of life-sustaining therapies, such as mechanical ventilation (invasive or non-invasive) or vasopressor therapy
Severe COVID -19	Defined by any of: <ul style="list-style-type: none"> • oxygen saturation < 90% on room air. • respiratory rate > 30 breaths per minute in adults and children > 5 years old; ≥ 60 in children less than 2 months; ≥ 50 in children 2–11 months; and ≥ 40 in children 1–5 years old. • signs of severe respiratory distress (i.e. accessory muscle use, inability to complete full sentences; and in children, very severe chest wall indrawing, grunting, central cyanosis, or presence of any other general danger signs).
Non-severe COVID-19	Defined as absence of any signs of severe or critical COVID-19.
<p>Caution: The panel noted that the oxygen saturation threshold of 90% to define severe COVID-19 was arbitrary and should be interpreted cautiously when used for determining which patients should be offered systemic corticosteroids. For example, clinicians must use their judgement to determine whether a low oxygen saturation is a sign of severity or is normal for a given patient suffering from chronic lung disease. Similarly, a saturation above 90–94% on room air may be abnormal if the clinician suspects that this number is on a downward trend. Generally, if there is any doubt, the panel suggested erring on the side of considering the illness as severe.</p>	

DECLARATIONS

Ethics approval and consent to participate

Institutional approval was granted and ethics requirement was waived for this manuscript by the Mulungushi University Ethics Review Committee number SMHS-MUI-2021-01. This case series study was done as part of a quality improvement project for the local management of hospitalised COVID-19 patients. The files were reviewed retrospectively and all subjects were deidentified.

Consent for publication

Not applicable.

Competing interests

Authors declare no competing interests.

Funding

There was no external funding for this manuscript.

Acknowledgements

Not applicable.

REFERENCES

1. Organisation WH. WHO Director-General's opening remarks at the media briefing on COVID-19 - 11 March 2020. WHO Dir Gen speeches [Internet]. 2020;(March):4. Available from: <https://www.who.int/dg/speeches/detail/who-director-general-s-opening-remarks-at-the-media-briefing-on-covid-19---11-march-2020>
2. Zheng KI, Feng G, Liu W-Y, Targher G, Byrne CD, Zheng M-H. Extrapulmonary complications of COVID-19: A multisystem disease? *J Med Virol* [Internet]. 2020 Jul 10;10.1002/jmv.26294. Available from: <https://pubmed.ncbi.nlm.nih.gov/32648973>
3. Behzad S, Aghaghazvini L, Radmard AR, Gholamrezanezhad A. Extrapulmonary manifestations of COVID-19: Radiologic and clinical overview. *Clin Imaging* [Internet]. 2020/05/18. 2020 Oct;66:35–41. Available from: <https://pubmed.ncbi.nlm.nih.gov/32425338>
4. Escher R, Breakey N, Lämmle B. Severe COVID-19 infection associated with endothelial activation. *Thromb Res* [Internet]. 2020 Apr 15;190:62. Available from: <https://pubmed.ncbi.nlm.nih.gov/32305740>
5. Varga Z, Flammer AJ, Steiger P, Haberecker M, Andermatt R, Zinkernagel AS, et al. Endothelial cell infection and endotheliitis in COVID-19. *Lancet* (London, England) [Internet]. 2020/04/21. 2020 May 2;395(10234):1417–8. Available from: <https://pubmed.ncbi.nlm.nih.gov/32325026>
6. Chen L, Li X, Chen M, Feng Y, Xiong C. The ACE2 expression in human heart indicates new potential mechanism of heart injury among patients infected with SARS-CoV-2. *Cardiovasc Res* [Internet]. 2020 May 1;116(6):1097–100. Available from: <https://pubmed.ncbi.nlm.nih.gov/32227090>
7. Green SJ. Covid-19 accelerates endothelial dysfunction and nitric oxide deficiency. *Microbes Infect* [Internet]. 2020/05/16. 2020;22(4–5):149–50. Available from: <https://pubmed.ncbi.nlm.nih.gov/32425647>
8. Tobin MJ. Basing Respiratory Management of COVID-19 on Physiological Principles. *Am J Respir Crit Care Med* [Internet]. 2020 Jun 1;201(11):1319–20. Available from: <https://pubmed.ncbi.nlm.nih.gov/32281885>
9. Dhont S, Derom E, Van Braeckel E, Depuydt P, Lambrecht BN. The pathophysiology of 'happy' hypoxemia in COVID-19. *Respir Res* [Internet]. 2020;21(1):198. Available from: <https://doi.org/10.1186/s12931-020-01462-5>