

CASE REPORT

# Spinal Haemangioblastomas: A Report of Two Cases

O.A Badejo<sup>1,2</sup>, T.A Oyemolade<sup>2</sup>, T.A Malomo<sup>2</sup>

<sup>1</sup>Division of Neurological Surgery, Department of Surgery, College of Medicine, University of Ibadan, Nigeria

<sup>2</sup>Department of Neurological Surgery, University College Hospital, Ibadan, Nigeria

## ABSTRACT

**Background:** Spinal haemangioblastomas are rare benign but potentially devastating vascular tumours. They may occur sporadically or as a component of Von Hippel-Lindau (VHL) disease. There is a dearth of information about these tumours among Nigerians. This study aims to evaluate the clinical profile and outcome of surgery as well as the challenges of management of these tumours in a resource-limited country.

**Methods:** We retrospectively analysed data from the records of patients who had surgery for spinal haemangioblastoma at our center between January 2004 and December 2018.

**Results:** We operated 2 cases of spinal haemangioblastomas during the study period (1 male, 1 female). The patients were aged 25 and 50 years. Both patients presented with sensorimotor deficits but only one of them had sphincteric dysfunction. The duration of symptoms was 2 weeks in one patient and 18 months in the other. The tumour was located in the thoracic region in both of them. One patient had extramedullary tumour while the other had an intramedullary spinal tumour. Both patients were paraplegic at the time of surgery, for 3 days in one patient and more than 4 months in the second patient. Gross total tumour resection was achieved in both individuals. The patient with short

duration of symptoms and extramedullary tumour made a rapid post-operative neurological improvement while the one with long duration of symptoms and intramedullary tumour remained paraplegic until his demise 9 months after surgery.

**Conclusion:** Spinal haemangioblastomas are rare tumours. Long duration of symptoms and intramedullary tumour location are predictors of unfavorable surgical outcome.

## INTRODUCTION

Haemangioblastomas are benign vascular tumours of the central nervous system.<sup>1,2,3,4</sup> They may occur sporadically (75%) or as a component of von Hippel-Lindau (VHL) disease (25%).<sup>1</sup> Common locations in the CNS include the cerebellum (44%–72%), spinal cord (13%–50%), brainstem (10%–20%), supratentorial region (<1%), and lumbosacral nerve roots (<1%) (5). Spinal cord haemangioblastomas are relatively rare, accounting for only 2% to 6% of all spinal cord tumours.<sup>1,6</sup> In spite of their benign nature, they can result in clinically devastating morbidities to the affected patients due to severe neurological deficits resulting from tumour mass, perilesional oedema, cyst or syrinx.<sup>1,3,4,7</sup> There is a paucity of information on spinal tumours, particularly spinal haemangioblastomas, in Sub-Saharan Africa. We present a report of two cases of sporadic spinal haemangioblastomas in Nigerian patients. To the best of our knowledge, this is the first report on these tumours from our country.

### Corresponding author:

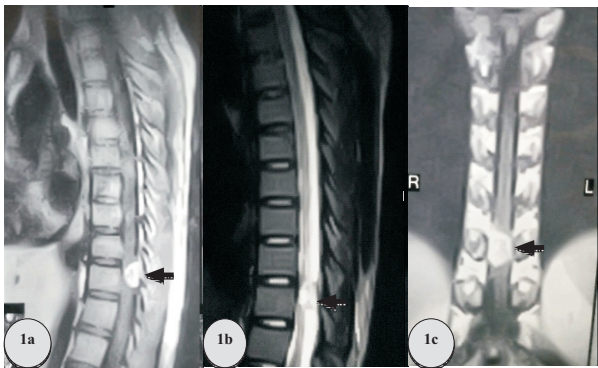
Dr. Oluwakemi. A. Badejo  
Division of Neurological Surgery, Department of Surgery,  
College of Medicine, University of Ibadan.  
Email: kemibadejo@yahoo.com  
Phone: +2348097317732

**Key words:** Haemangioblastoma, Spinal cord, Nigerian, Surgery, Outcome

## CASE REPORTS

### Case 1:

25-year-old right handed female who presented with right flank pain, numbness and paraesthesia of the lower extremities of two weeks' duration. She developed progressive paraparesis about ten days later. Her symptoms were not associated with sphincteric dysfunction. Examination revealed full power in the upper extremities. She however had a spastic paraparesis which was significantly worse on the right (grade 1-3), hyperreflexia (worse in the lower limbs) and sustained ankle clonus bilaterally. Her plantar response was extensor on the right and flexor on the left. She had a sensory level of T9. There were no features suggestive of VHL. Magnetic resonance imaging of the thoracic spine showed a T10 intradural-extramedullary lesion (Figure 1 a-c).



**Figure 1: Preoperative thoracic spine magnetic resonance imaging of the first patient (black arrow on the intradural-extramedullary tumour).**

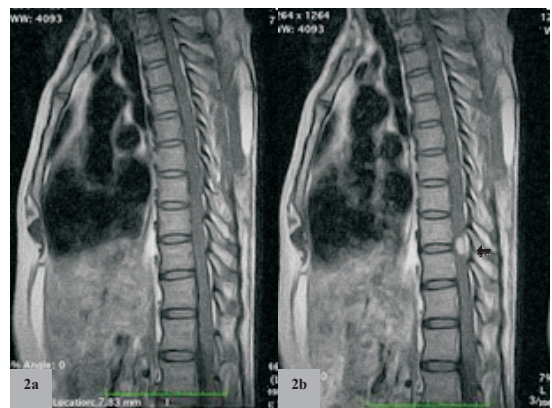
- a: Sagittal T1-weighted image. Note the dorsal location of the lesion (which favours a posterior surgical approach) and the significant spinal cord compression.**
- b: Sagittal T2-weighted image.**
- c: Coronal T1-weighted image. Note that the lesion is mainly right-sided which corresponds with the patient's clinical presentation.**

She had further neurologic deterioration (from Frankel C to B) a week after presentation while

sourcing for funds for her care. She subsequently had (partial) T9/T10 laminectomies and gross total tumour excision. Her postoperative recovery was satisfactory with progressive improvement in motor functions of the lower limbs. She was discharged home twenty-two days after her surgery with lower limb power of grade 4 to 4<sup>+</sup>. On follow-up evaluation five weeks post-operatively, she had full muscle power in the lower limb muscle groups, except for the hip and knee extension. At six months follow-up, she had regained full power in all the muscle groups of the lower extremities. Histology was in keeping with a capillary haemangioblastoma.

### Case 2:

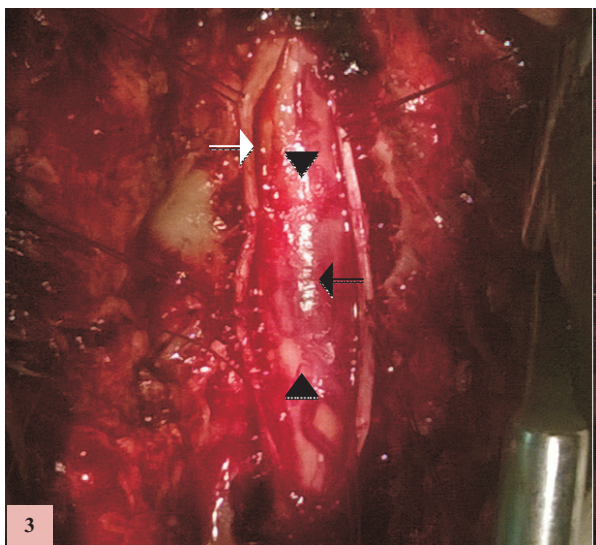
50-year-old right handed man who presented with low back pain and progressive paraparesis of eighteen months, and three months, duration respectively. He had no co-morbidities. Examination revealed a middle-aged man with normal general examination findings. His long tracts were normal in the upper limbs. He had a spastic paraparesis with power being grade 4<sup>-</sup> to 4<sup>+</sup> in the right lower limb and 4 to 5 in the left lower limb. Sensory level was T7 bilaterally with residual to S4 and S5. Magnetic resonance imaging of the thoracic spine revealed a T9/T10 contrast-enhancing intramedullary tumour (Fig. 2).



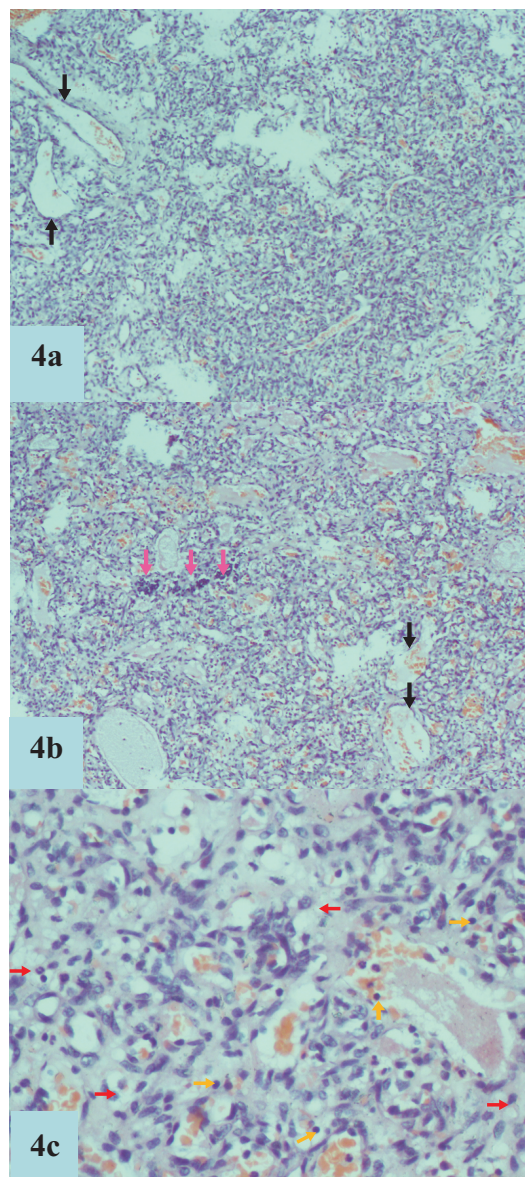
**Figure 2: Preoperative thoracic spine magnetic resonance imaging of the second patient.**

- a: Sagittal T1-weighted image (pre-contrast).**
- b: Contrast-enhanced sagittal T1-weighted image showing an intramedullary tumour (black arrow).**

The patient initially declined surgical treatment and presented two months later with complete neurologic dysfunction infected grade IV mid-sacral decubitus ulcer and septicaemia. He had wound debridement and broad-spectrum intravenous antibiotic therapy. Following resolution of sepsis a month later, he had T8-T10 laminectomies and gross total tumor excision (Fig. 3). Histology revealed a haemangioblastoma (Fig. 4). He made no neurologic gains postoperatively and was discharged home after five months of hospitalisation following healing of his pressure sore. However, he was readmitted three months later due to multiple bed sores (including a grade IV recurrent infected mid-sacral pressure ulcer) and septic shock. There was repetitive faecalsoilage of the ischial component of the bedsores with waxing and waning systemic sepsis throughout his hospitalization. The patient refused a colostomy. He developed multi-organ dysfunction terminally and died nine months postoperatively.



**Figure 3:** Intraoperative photograph of the second patient after T8-T10 laminectomies and a durotomy. Note the purplish discoloration of the spinal cord at the site of the tumour (black arrow). The white arrow is on the dural edge and the black arrow heads on the cord proximal and distal to the lesion.



**Figure 4:** Photomicrograph of the hematoxylin and eosin staining of the surgical specimen of the second patient showing a benign mesenchymal neoplasm composed of proliferating stroma cells (red arrows). These cells have oval to spindle shaped nuclei with moderate to abundant vacuolated cytoplasm. The nuclei are mildly pleomorphic and hyperchromatic. Also seen are occasionally tumour giant cells with degenerate, markedly pleomorphic nuclei. There are multiple interspersed vascular channels (black arrows on the larger feeder vessels) and stromal infiltration by neutrophils (pink arrows), mast cells, lymphocytes (yellow arrows) and areas of hemosiderin-laden macrophages. These features are in keeping with a haemangioblastoma.

**Table 1: Demographic and clinical characteristics of the patients.**

SN	Age (years)	Sex	Duration of symptoms	Spinal region	Tumour location	Pre-operative Frankel grading	Post-Operative Frankel grading	Duration of follow-up
1	25	F	2 weeks	Thoracic	Extra-medullary	*A	E	2 years
2	50	M	18 months	Thoracic	Intra-medullary	**A	A	9 months

\*Frankel grading was C at presentation but deteriorated to B prior to surgical intervention.

\*\*Frankel grading was D at initial review but declined to A before surgery.

## DISCUSSION

Spinal haemangioblastomas are relatively rare tumours accounting for 2-6% of spinal cord tumours.<sup>6,8</sup> They may occur sporadically or as part of VHL syndrome.<sup>1</sup> Although histologically benign, these tumours can cause significant neurological deficits because of their location.<sup>1,3,4,7</sup> Between January 2004 and December 2018, we operated 2 patients with spinal haemangioblastoma, accounting for 2.1% of the operated cases of spinal tumours in our centre during the period. This is in keeping with the reported incidence of these tumours.<sup>6</sup>

Male predominance of spinal haemangioblastomas has been documented, with a reported male to female ratio ranging between 1.6:1 to 5.5:1.<sup>3,8,9,10,11,12</sup> The male gender accounted for 72.7% of the cases in the series by Yasuda *et al* and 75% of the case in the series by Park *et al*.<sup>8,12</sup> Conversely, there were more females in the study by Das *et al* with the male gender accounting for 42.9% of the patients' population.<sup>1</sup> Our patients were equally distributed between the two genders. Spinal haemangioblastomas commonly occur in the third

and fourth decades of life, although occurrences in patients on either sides of this age range have been documented.<sup>1,8,12</sup> The average age was 33.5 years in the series by Das *et al* and 53.9 years in the series by Yasuda *et al*.<sup>1,8</sup> The younger of our patients was in the third decade of life, while the older one was in the sixth decade.

These tumours may present clinically with motor, sensory or autonomic deficits. In the series by Das *et al* motor weakness was present in 86% of the patients at presentation, sensory deficits in 79% and bladder disturbance in 21%.<sup>1</sup> Pain was the presenting symptom in 29% of their patients. Motor weakness and sensory deficits were the most common presenting symptoms in the study by Park *et al* each occurring in 50% of the cases.<sup>12</sup> Our patients had sensorimotor deficits at presentation but sphincteric dysfunction was present in only one of them.

Spinal haemangioblastomas are primarily intradural tumours and occur mostly in the cervical and thoracic regions.<sup>1,3,8,13,14,15</sup> In the series by Imagama *et al*, 84.6% of the tumours were intramedullary, 11.5% were intramedullary/extramedullary, and

3.8% were intradural-extramedullary.<sup>14</sup> Deng *et al* reported 41%, 37%, and 22%, respectively for the same groups of tumours respectively. The tumours were located in the thoracic region in our index patients (one intramedullary, and the other intradural-extramedullary). Patients with intradural-extramedullary haemangioblastomas tend to be older than the patients with intramedullary tumours.<sup>8,11,16,17,18,19,20</sup> Contrariwise, the younger of our patients had an intradural-extramedullary tumour location, which was intramedullary in the older patient.

Microsurgical resection remains the treatment of choice for spinal haemangioblastomas but radiosurgery has been used in some patients.<sup>15,21,22,23,24,25</sup> The outcome of the surgical management of these tumours depends on the preoperative neurological status of the patients, location/ volume of the tumour, duration of symptoms and the extent of surgical resection.<sup>1,2,4,12,26,27,28,29</sup> Good preoperative functional status, complete tumour excision, small size and dorsal tumour location are predictors of good postoperative outcome. Our 2 patients were paraplegic at the time of surgery, the first for about 3 days and the second for more than 4 months. They both had gross total resection of their tumours. The duration of symptoms was significantly shorter in the patient with postoperative neurological improvement who also had a favourable tumour location.

Our cases also highlighted the role of poverty, ignorance, and lack of social support in the outcome of neurological diseases in resource-poor countries. Whereas the first of our patients became paraplegic while sourcing for funds for surgery, the second patient (who had better educational and socio-economic status) initially declined surgery. He returned for further evaluation after the onset of paraplegia and sepsis from a mid-sacral decubitus ulcer which further delayed his surgery. Following discharge from the hospital, his lack of social support contributed to his development of multiple decubitus ulcers and sepsis which eventually led to

his demise. Of note is the intramedullary location of his tumour, a poor prognostic indicator.

## CONCLUSION

Spinal haemangioblastomas are relatively rare tumours. They are mostly located in the cervical and thoracic regions. Although benign, they can cause significant morbidity and even mortality. Poverty, ignorance and lack of social support continue to pose a serious challenge to the management of these tumours and other neurological diseases in the developing countries.

## Conflict of interest

The authors report no conflicts of interest.

## Funding

This research did not receive any specific grant from funding agencies in the public, commercial, or not-for-profit sectors.

## REFERENCES

1. Das JM, Kesavapisharady K, Sadasivam S, Nair SN. Microsurgical treatment of sporadic and von Hippel-Lindau disease associated spinal Hemangioblastomas: a single-institution experience. *Asian Spine J.* 2017;11(4):548–55. <https://doi.org/10.4184/asj.2017.11.4.548>
2. Lee DK, Choe WJ, Chung CK, Kim HJ. Spinal cord hemangioblastoma: surgical strategy and clinical outcome. *J Neurooncol.* 2003;61:27–34.
3. Mandigo CE, Ogden AT, Angevine PD, McCormick PC. Operative management of spinal hemangioblastoma. *Neurosurgery.* 2009;65:1166–1177.
4. Na JH, Kim HS, Eoh W, Kim JH, Kim JS, Kim ES. Spinal cord hemangioblastoma: diagnosis and clinical outcome after surgical treatment. *J Korean Neurosurg Soc.* 2007;42:436–440.
5. Pluta RM, Wait SD, Butman JA, et al. Sacral hemangioblastoma in a patient with von Hippel-Lindau disease: case report and review of the literature. *Neurosurg Focus.* 2003;15:E11.
6. Mehta GU, Asthagiri AR, Bakhtian KD, Auh S, Oldfield EH, Lonser RR. Functional outcome

- after resection of spinal cord hemangioblastomas associated with von Hippel-Lindau disease. *J Neurosurg Spine*. 2010;12:233–242.
7. Richard S, Campello C, Taillandier L, Parker F, Resche F. Haemangioblastoma of the central nervous system in von Hippel-Lindau disease. *J Intern Med*. 1998;243:547–553
  8. Yasuda T, Hasegawa T, Yamato Y, et al. Relationship between spinal hemangioblastoma location and age. *Asian Spine J* 2016;10:309–313. doi: 10.4184/asj.2016.10.2.309
  9. Chu BC, Terae S, Hida K, Furukawa M, Abe S, Miyasaka K. MR findings in spinal hemangioblastoma: correlation with symptoms and with angiographic and surgical findings. *AJNR Am J Neuroradiol*. 2001;22:206-217.
  10. Conway JE, Chou D, Clatterbuck RE, Brem H, Long DM, Rigamonti D. Hemangioblastomas of the central nervous system in von Hippel-Lindau syndrome and sporadic disease. *Neurosurgery*. 2001;48:55-62.
  11. Barbosa-Silva E, Carvalho GT, Frota Mde O, Sousa AA, Souza CB. Intradural extramedullary hemangioblastoma. *Arq Neuropsiquiatr*. 2009;67:530–533.
  12. Park CH, Lee CH, Hyun SJ, Jahng TA, Kim HJ, Kim KJ. Surgical outcome of spinal cord hemangioblastomas. *J Korean Neurosurg Soc*. 2012;52(3):221–227. <https://doi.org/10.3340/jkns.2012.52.3.221>.
  13. Deng X, Wang K, Wu L, et al. Intraspinous hemangioblastomas: analysis of cases in a single institution: clinical article. *J Neurosurg Spine*. 2014;21:260-169.
  14. Imagama S, Ito Z, Wakao N, et al. Differentiation of localization of spinal hemangioblastomas based on imaging and pathological findings. *Eur Spine J*. 2011;20:1377-1384
  15. Lonsler RR, Oldfield EH. Spinal cord hemangioblastomas. *Neurosurg Clin N Am*. 2006;17:37–44.
  16. Wisoff HS, Suzuki Y, Llena JF, Fine DI. Extramedullary hemangioblastoma of the spinal cord: case report. *J Neurosurg*. 1978;48:461-464.
  17. Brisman JL, Borges LF, Ogilvy CS. Extramedullary hemangioblastoma of the conus medullaris. *Acta Neurochir (Wien)* 2000;142:1059-1062
  18. Taniguchi S, Ogikubo O, Nakamura T, et al. A rare case of extramedullary-intradural hemangioblastoma in the thoracic spine. *Spine (Phila Pa 1976)* 2009;34:E969-E972.
  19. Kitanaka C, Kuwahara M, Teraoka A. Intradural, purely extramedullary hemangioblastoma of the spinal cord: case report. *Neurol Med Chir (Tokyo)* 1993;33:377–380.
  20. Toyoda H, Seki M, Nakamura H, Inoue Y, Yamano Y, Takaoka K. Intradural extramedullary hemangioblastoma differentiated by MR images in the cervical spine: a case report and review of the literature. *J Spinal Disord Tech*. 2004;17:343–347
  21. Roonprapunt C, Silvera VM, Setton A, Freed D, Epstein FJ, Jallo GI. Surgical management of isolated hemangioblastomas of the spinal cord. *Neurosurgery* 2001;49(2):321–327; discussion 327–328.
  22. Ammerman JM, Lonsler RR, Dambrosia J, Butman JA, Oldfield EH. Long-term natural history of hemangioblastomas in patients with von Hippel-Lindau disease: implications for treatment. *J Neurosurg* 2006;105(2):248–55.
  23. Cohen-Gadol AA, Spencer DD, Krauss WE. The development of techniques for resection of spinal cord tumors by Harvey W. Cushing. *J Neurosurg Spine* 2005;2(1):92–97.
  24. Parsa AT, Chi JH, Acosta FL, Ames CP, McCormick PC. Intramedullary spinal cord tumors: molecular insights and surgical innovation. *Clin Neurosurg* 2005;52:76–84.
  25. Moss JM, Choi CY, Adler JR, Soltys SG, Gibbs IC, Chang SD. Stereotactic radiosurgical treatment of cranial and spinal hemangioblastomas. *Neurosurgery*. 2009. 65: 79-85
  26. Shin DA, Kim SH, Kim KN, Shin HC, Yoon DH. Surgical management of spinal cord

- haemangioblastoma. *Acta Neurochir* (Wien) 2008;150:215–220. discussion 220.
27. Takai K, Taniguchi M, Takahashi H, Usui M, Saito N. Comparative analysis of spinal hemangioblastomas in sporadic disease and Von Hippel-Lindau syndrome. *Neurol Med Chir* (Tokyo) 2010;50:560–567.
28. Boström A, Hans FJ, Reinacher PC, et al. Intramedullary hemangioblastomas : timing of surgery, microsurgical technique and follow-up in 23 patients. *Eur Spine J*. 2008;17:882–886
29. Lonser RR, Weil RJ, Wanebo JE, DeVroom HL, Oldfield EH. Surgical management of spinal cord hemangioblastomas in patients with von Hippel-Lindau disease. *J Neurosurg*. 2003;98:106–116.